SLC - Riunioni Scientifiche «under 40»

Genova, 31/03/2016

Ricostruzione della parete addominale tramite tecniche anatomiche

Enrico Perino

Università degli Studi di Genova
Dipartimento di Scienze Chirurgiche
U.O. Clinica Chirurgica 2
IRCCS A.O.Universitaria San Martino – IST
Direttore Prof Ezio Gianetta

Caso clinico

- Paziente *R.E.*
- Sesso *maschio*
- Età *68 aa*
- BMI *24,9 kg/m²*

Anamnesi Patologica Remota

- Diabete mellito II in terapia insulinica
- Psoriasi
- 1966 Appendicectomia
- 1997 Exeresi cisti di Baker ginocchio dx
- 2010 TURP per ipertrofia prostatica benigna
- 2013 DCP per K papilla di Water istologico pT2N0G2

Presentazione clinica

APP

- Riferisce tumefazione addominale dolorante, molle, in crescita rapida che confligge con le normali attività
- Associata sintomatologia dolorosa

E.O.

- Laparocele mediano xifo – ombelicale 19 x9 cm
- Notevole lateralizzazione dei retti

Esami ematochimici e radiologici

- Marcatori nella norma
- TC presenza di linfadenomegalie mesenteriche stabili da un anno
- PET negativa

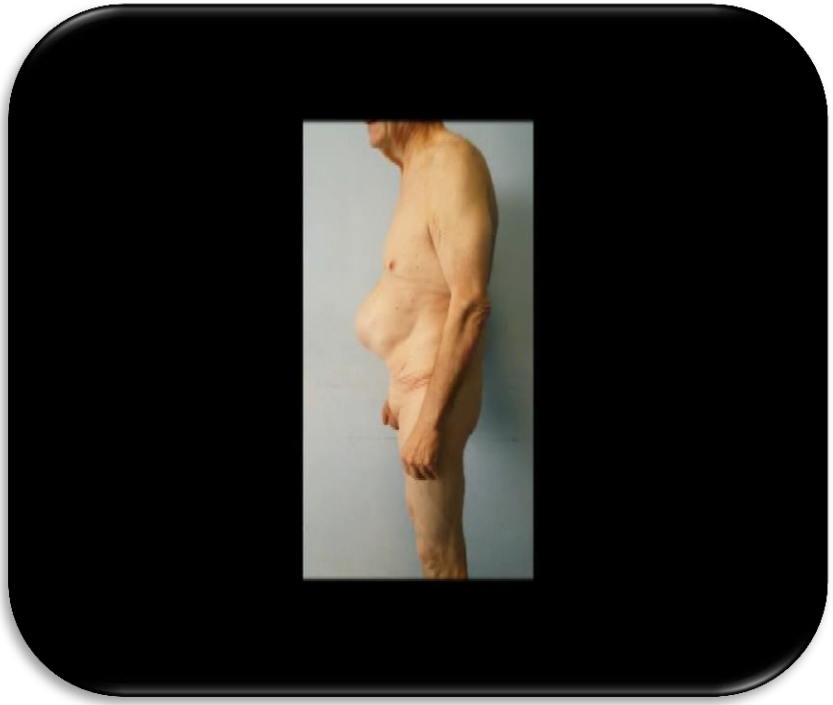

Quale percorso preoperatorio?

Quale percorso preoperatorio I?

- TC SMDC DINAMICA

- VOLUMETRIA

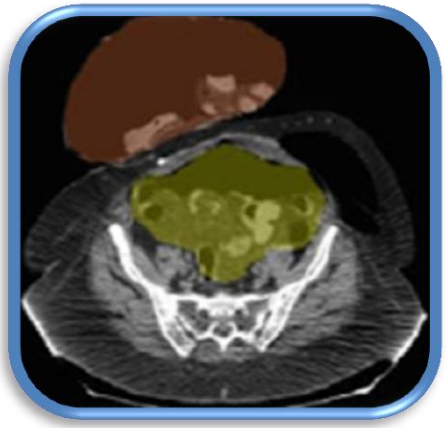

IHV

ACV

\+ PV

un rapporto **IHV/PV < 20 % è** predittivo di una chiusura tension free

Sabbagh et al, Hernia (2011) 15:559–565

Quale percorso preoperatorio I?

TC

- Presenza di laparocele mediano xifo-ombelicale di diametro cranio-caudale di 19 cm. I retti appaiono notevolmente lateralizzati, il diametro è di 9 cm sotto manovra di Valsalva…

Volumetria

- IHV 3705 cm^3
- ACV 8251 cm^3
- PV 11956 cm^3
- **IHV/PV 30,9%**

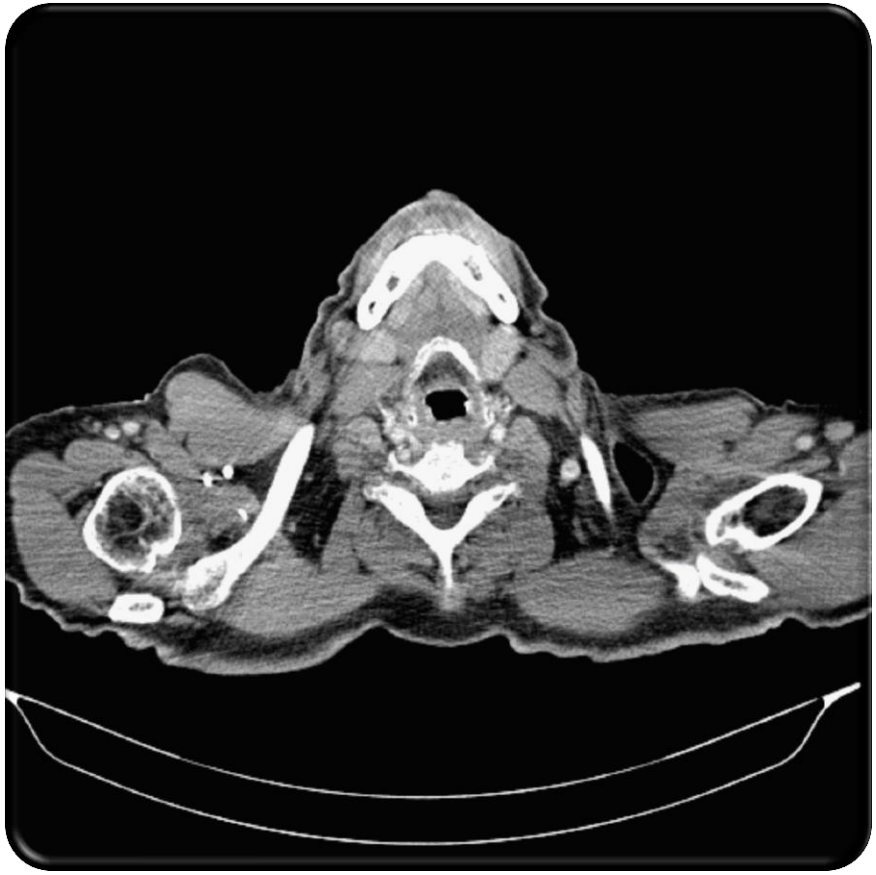

Quale intervento chirurgico proporreste e perchè?

...Solitamente...

La Rives-Stoppa è il goldstandard, sempre fare la Rives!!!

Salvo poi....

- «Non viene, tira....»
- «Amen mettiamo una rete intraperitoneale»
- «Amen mettiamo un patch di vicryl»
- «Dammi la dualmesh»
- «Con l'omento va bene uguale»
- «Facciamo una Ramirez»

giant incisional hernia: when > 15cm explanation

occurrence

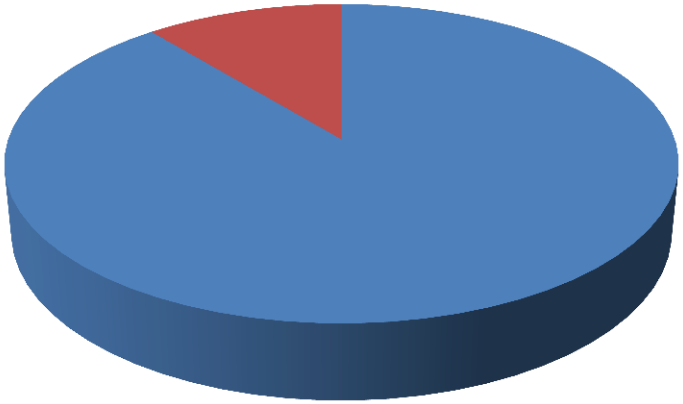

< 15 cm

>15

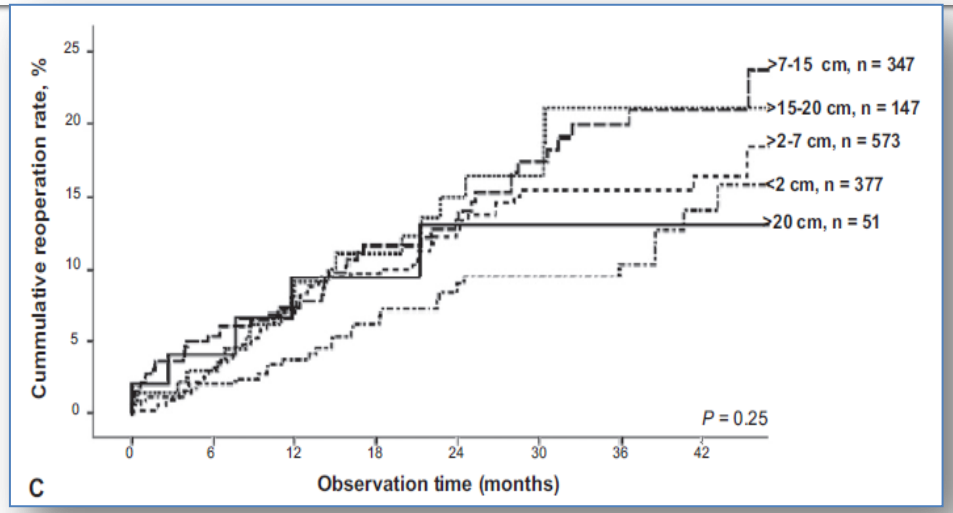

Table 5. Multivariate Analyses of Risk Factors for Outcomes after Incisional Hernia Repair, Logistic, and Cox Regression

	Dependent variable			
	Readmission (n = 433)	Reoperation (n = 71)	Mortality (n = 16)	Recurrence repair (n = 310)
Independent variables	OR (95% CI)	OR (95% CI)	OR (95% CI)	HR (95% CI)
Defect, cm				
>0–2	1	1	NS	1
>2–7	1.5 (1.1–2.3)*	1.1 (0.3–4.3)	NS	1.2 (0.8–1.8)
>7–15	1.7 (1.2–2.6)*	4.2 (1.3–14.1)*	NS	1.7 (1.2–2.6)*
>15–20	2.5 (1.6–3.8)*	6.4 (1.9–22.4)*	NS	1.6 (1.0–2.6)*
>20	1.6 (0.9–3.0)	6.7 (1.7–26.7)*	NS	2.4 (1.4–4.2)*

Halgstrand F, J Am Coll Surg 2012; 216: 217-28

Figures for repair of hernias >15 cm

	median	range
overall morbidity	32%	4-100%
wound infection rate	10%	0 - 33%
mortality	0%	0 - 5%
recurrence	5%	0 - 53%

Eriksson A et al. Hernia 2013

Quale intervento?

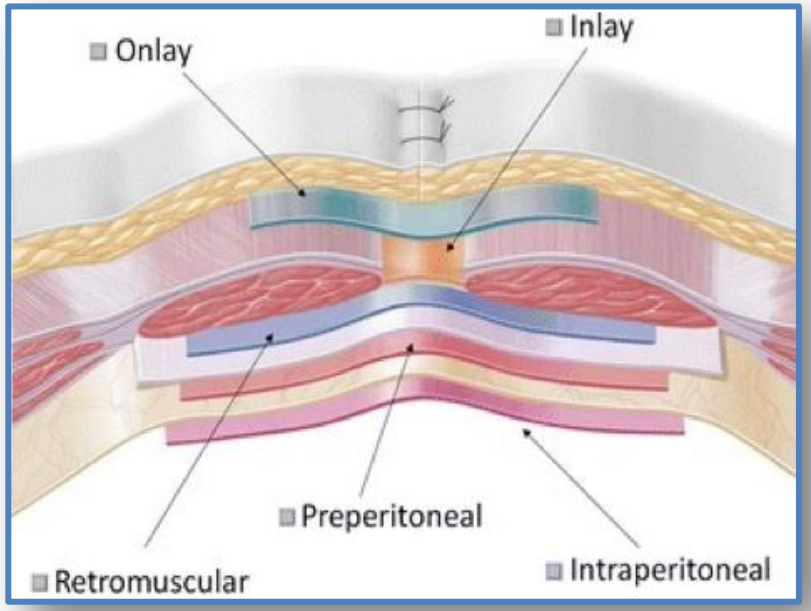

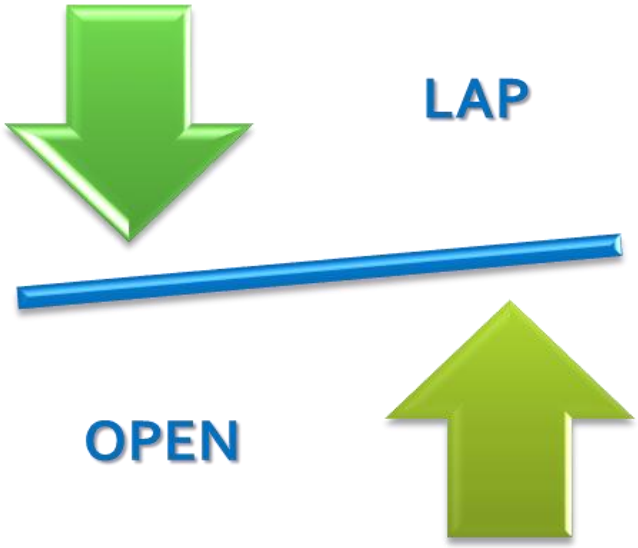

Literature results for hernias >15 cm according to different technique

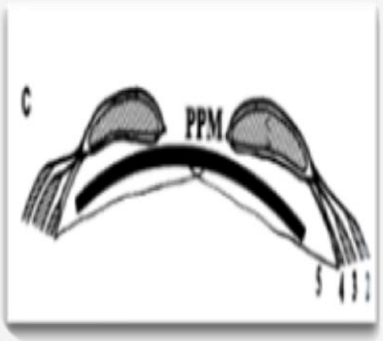

ONLAY

- Morbidity rates 11%
- Recurrence 11%
- Reop for infection 9%

INL

- re %

SUBLAY (Rives-Stoppa)

- 1 RCT sublay ePTFE vs Component separation
- Morbidity 83%
- Recurrence 22%

INTRAPERIT ONEAL

- Morbidity 4-16%
- Mortality 0 – 0,8%
- Recurrence rate 0 - 3%

L’intervento chirurgico

Domande aperte

- 1 ha senso la ricostruzione della linea mediana?
- 2 quale è il destino delle protesi intraperitoneali?
- 3 quale è il ruolo della Ramirez?

1 Perché ricostruire la linea mediana

2015

Studi dinamometrici

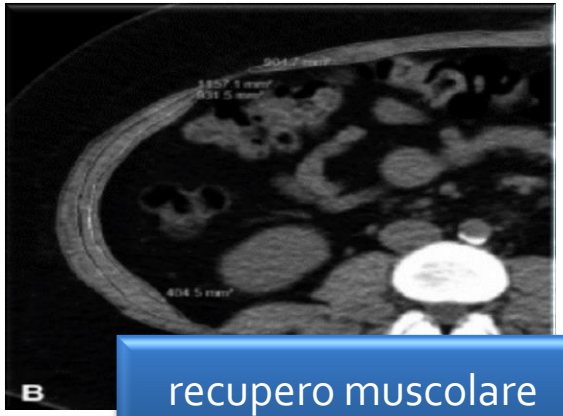

recupero muscolare

2014



2015

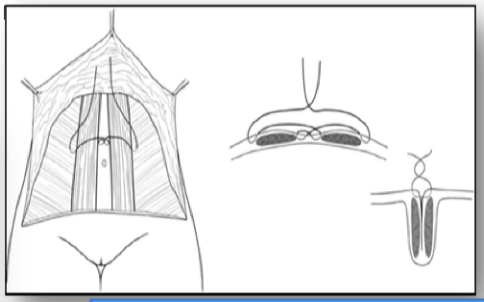

Riduzione del dolore spinale

2 Le protesi intraperitoneali

- permettono di risolvere i casi di perdita di sostanza
- hanno aperto la strada alla laparoscopia *(nei difetti >10 cm necessità di ulteriore esperienza chirurgica)*
- sicurezza
  - ePTFE: *debole verso le infezioni e viene incapsulato*
  - Protesi composite: *shrinkage, instabilità del lato antiaderenziale, mancanza di incorporazione*
  - mancanza di dati long-term
- **<u>grande spinta dell'industria</u>**

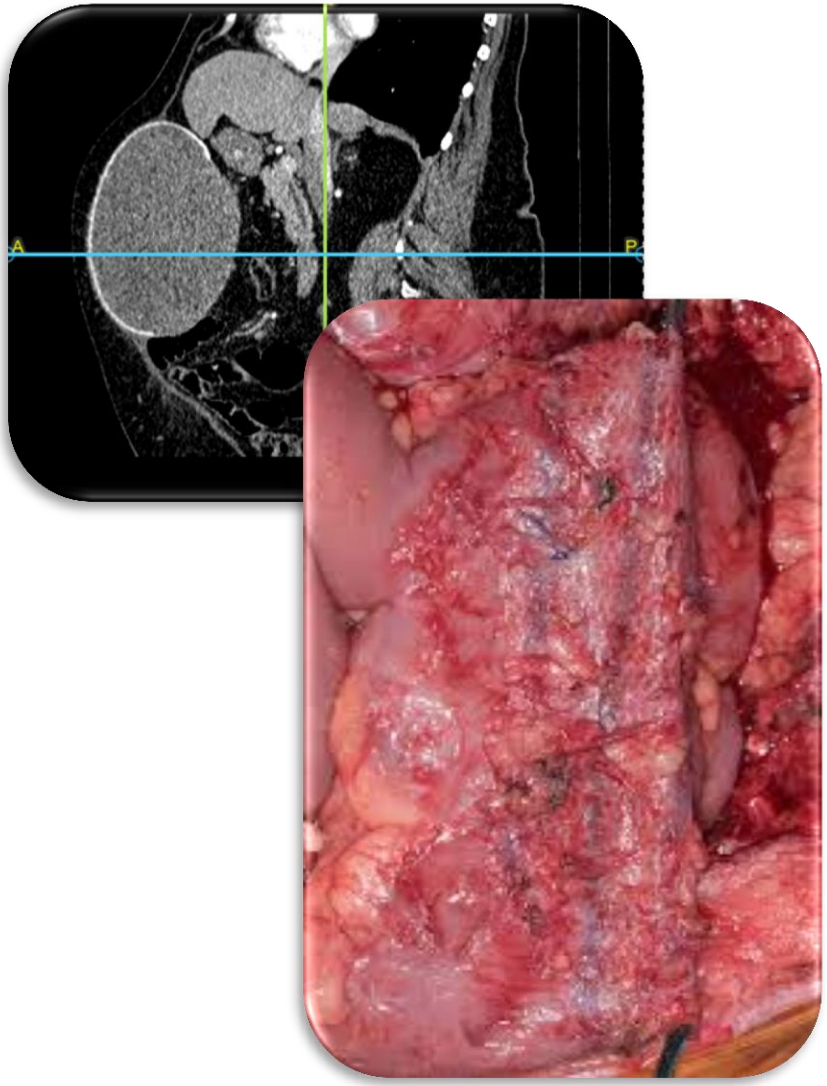

3 La component separation sec Ramirez

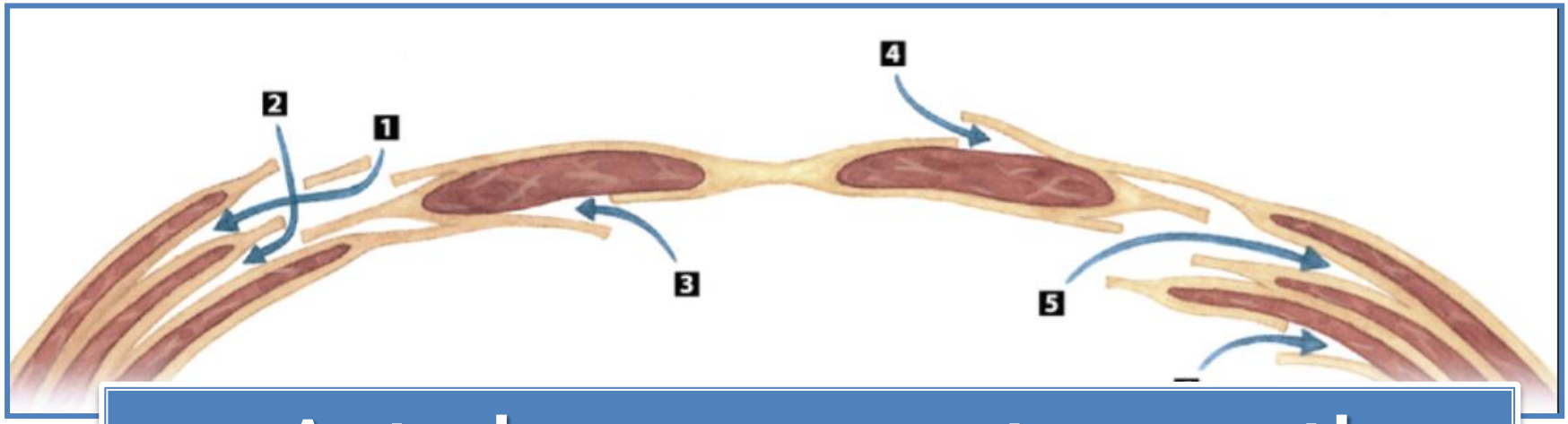

- Anterior component separation
- Transversus abdominis release

External & Internal Oblique Release	Levine (2001)	1 2
"Sliding Door" Release	Kuzbari (1998)	1 3 4
External Oblique/Transversus Abdominis Release	Thomas (1993)	1 6
External Oblique/Anterior Rectus Release	Lucas (1998)	1 4
Anterior Rectus Fascia Release	Yeh (1996)	4
"Lateral" Release	Mathes (2000)	5
Modified Components Separation Release	Fabian (1994)	1 2 3

Hernia recurrence and component separation

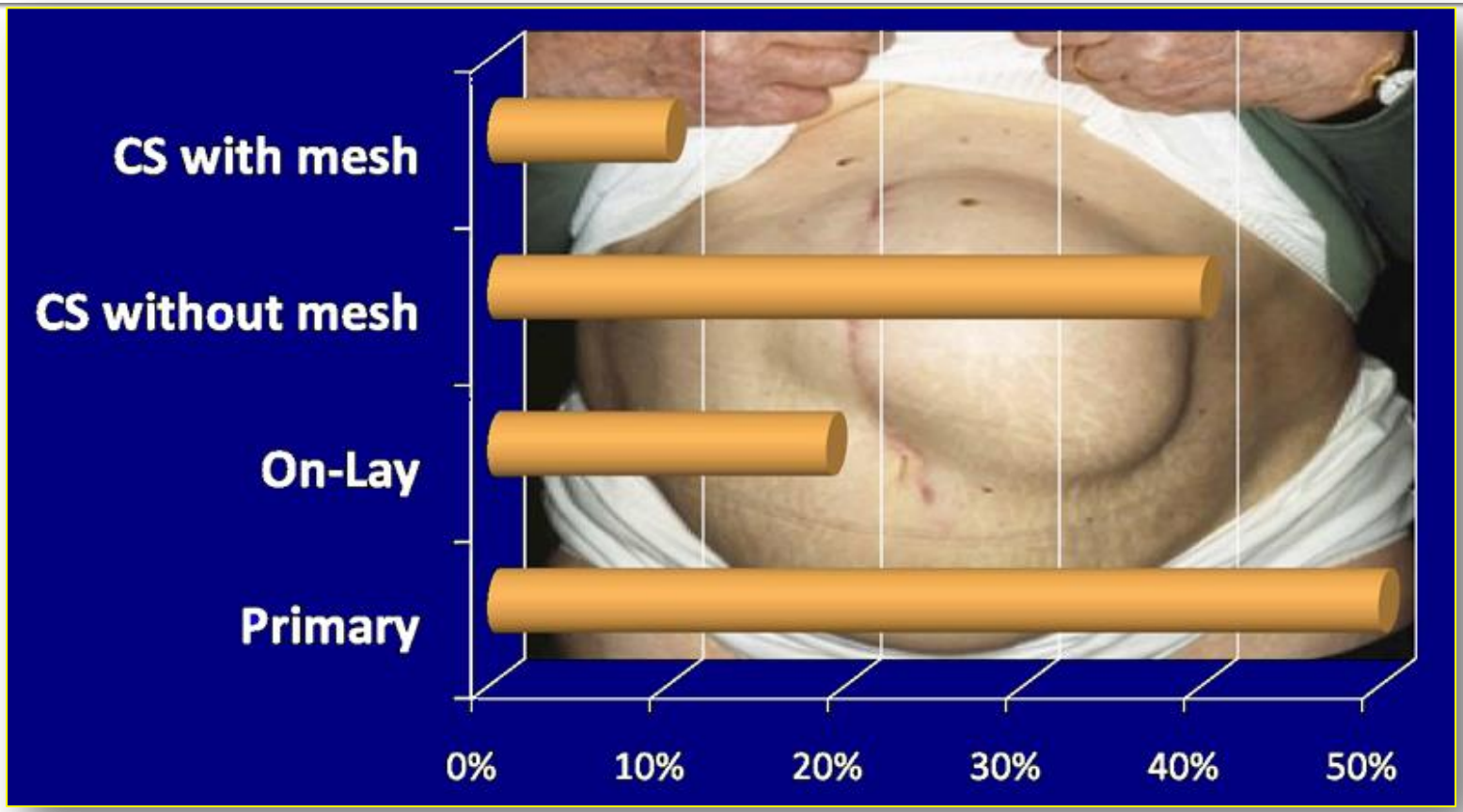

Van Geffen *Recurrent Hernia, 2007*
Den Hartog D et al. Cochrane Database Syst Rev.2008;
Fitzgibbons ACS Surgery: Principles and Practice

B

The American Journal of Surgery (2012) 203, 318–322

The American Journal of Surgery®

Midwest Surgical Association

Posterior and open anterior components separations: a comparative analysis

David M. Krpata, M.D.*, Jeffrey A. Blatnik, M.D., Yuri W. Novitsky, M.D.[1],

	ACS	TAR
Major wound complications	19,6%	10,9%
Minor wound complications	16%	14,5%
recurrence	14.3%	3,6%

In conclusione

*considered the **"gold standard"** technique because it restores the abdominal anatomy with calibred tension*

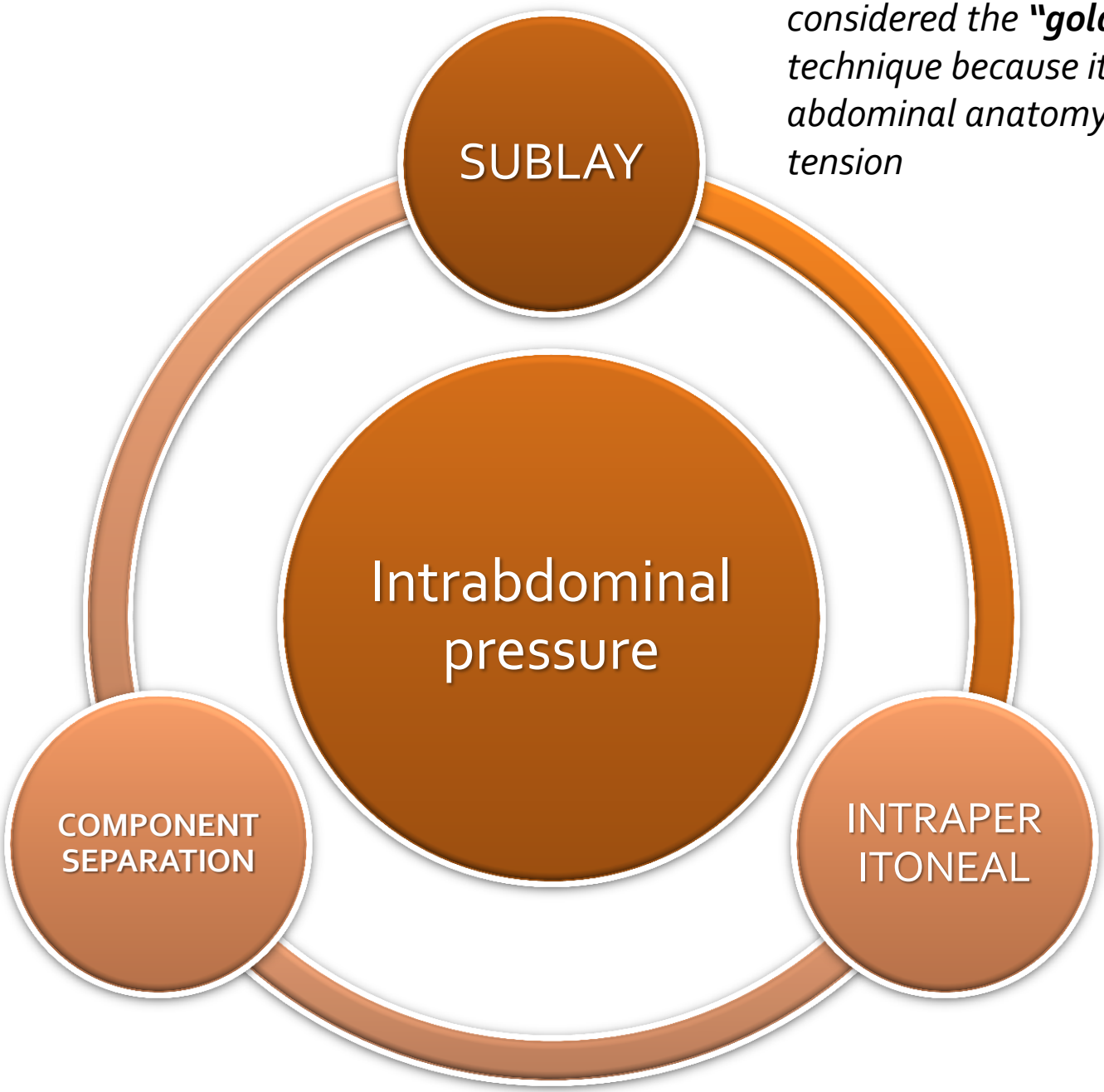

First choice:

- reapproximation of the muscle with Rives Stoppa procedure

When to quit Rives?

Loss of substance

+

Loss off domain

→

Abdominal hypertension

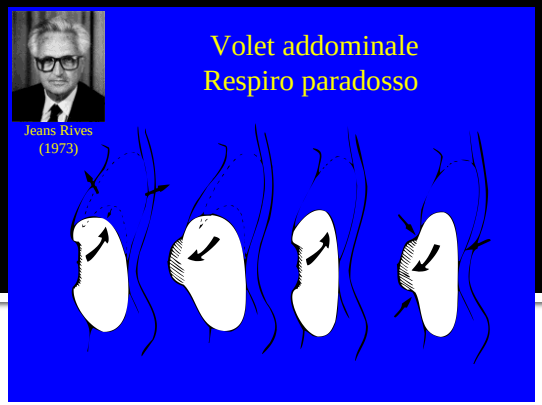

REMINDER

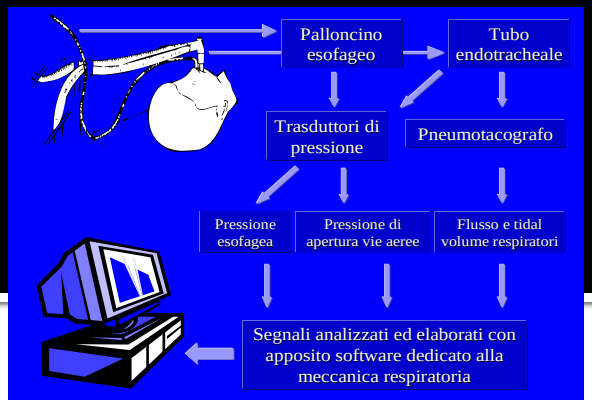

Allargare la cavità peritoneale!

- **Enlargement of the abdominal cavity**
- **Pathological rise of the pressure**
- **Measure of the intrabdominal pressure**
  - **(bladder catheter)**

Large incisional hernia

Attempted Rives Sublay

Grazie per l’attenzione

New measures of abdominal function

trunk flexor strength compared among

- patients submitted to laparoscopic hernia repair (14s)
- open hernia repair with rectal approximation without mesh (16 s)
- healthy subjects. (12s)

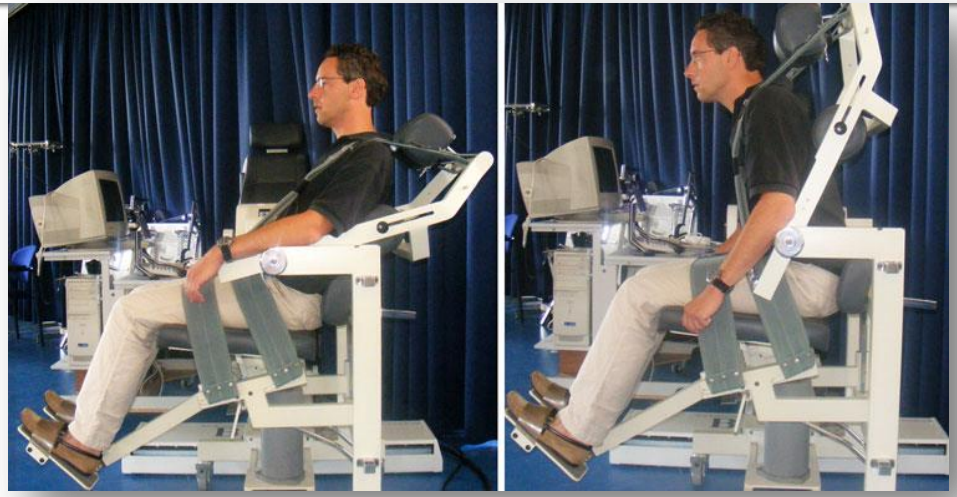

Table 1 Mean peak torque related to body weight in N m/kg (standard deviation [SD]) in trunk flexion comparing two different operations for incisional hernia with the control group (n = 12)

Peak torque/weight (N m/kg)	Operation group	Control group (n = 12)	Confidence interval of the difference	P-value
Total operation group (n = 30) versus control	84.4 (38.9)	202.4 (88.6)	60.5; 175.4	<0.01
No mesh = two-layered technique (n = 16) versus control	95.8 (39.7)	202.4 (88.6)	47.9; 165.3	<0.01
Laparoscopic (n = 14) versus control group	71.4 (34.8)	202.4 (88.6)	72.6; 189.4	<0.001

Table 2 Mean peak torque related to body weight in N m/kg (SD) in trunk flexion comparing the two operations for incisional hernia

Peak torque/weight (N m/kg)	Laparoscopic group (n = 14)	Two-layered technique (n = 16)	Confidence interval of the difference	P-value	Power post-hoc
Laparoscopic versus two-layered technique	71.4 (34.8)	95.8 (39.7)	−52.5; 3.6	0.086	0.41

Den Hartog D, Hernia 2010; 14: 243-47

Drawbacks of the study

1. the study was not prospective and largely underpowered.
2. patients in the open surgical group were submitted to a two-layered suture repair without mesh which is not an acceptable technique basing on current available data.
3. the provided results have a speculative and statistics relevance but the authors don't underline their clinical impact.
4. data on preoperative patients' trunk flexor strength are not available thus a correct evaluation of the surgical result is not possible.

Hartog D. Hernia. 2010:14:243-247.

Functional abdominal wall reconstruction improves core physiology and quality-of-life

Cory N. Criss, MD,[a] Clayton C. Petro, MD,[a] David M. Krpata, MD,[a] Christina M. Seafler, RN,[a] Nicola Lai, PhD,[b,c] Justin Fiutem, MS,[c] Yuri W. Novitsky, MD,[a] *and* **Michael J. Rosen, MD,[a]**
Cleveland, OH

Conclusion. *Restoration of the linea alba during VHR is associated with improved abdominal wall functionality. Analysis of rectus muscle function using a dynamometer showed statistical improvement by isokinetic and isometric measurements, all of which were associated with an improvement in quality-of-life. (Surgery 2014;156:176-82.)*

Comparative Radiographic Analysis of Changes in the Abdominal Wall Musculature Morphology after Open Posterior Component Separation or Bridging Laparoscopic Ventral Hernia Repair

Gayan S De Silva, BS, David M Krpata, MD, Caitlin W Hicks, MD, Cory N Criss, MD, Yue Gao, MD, PhD, Michael J Rosen, MD, FACS, Yuri W Novitsky, MD

Large ventral hernias are known to induce atrophic changes to the anterior abdominal wall

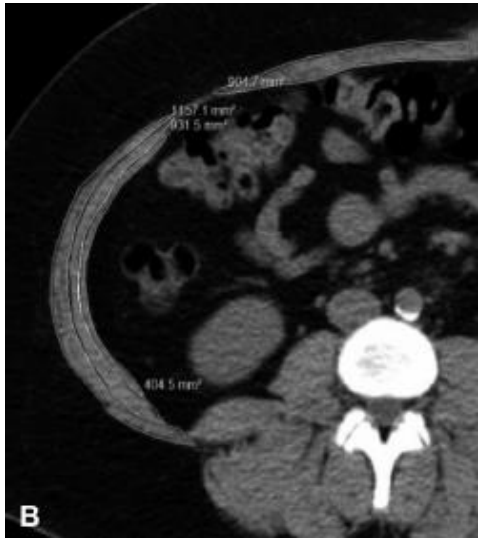

- Similar to anterior component separation, hernia repair with TAR results in hypertrophy of the rectus abdominis muscle.
- In addition TAR was associated with hypertrophy of both external and internal oblique muscles.
- Bridging repair during LVHR did not result in any significant changes in any of the abdominal muscles.

Functional Results of midline restoration

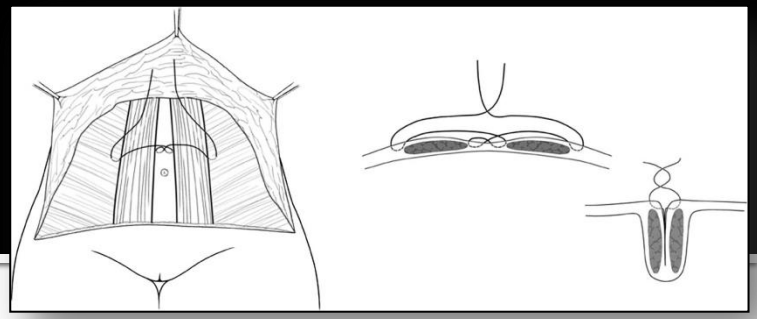

Chronic back pain

- Reported 95% healing of low back after wide rectus plication in patients
- Interventions that increase intraabdominal pressure have been shown to increase spine stability and decrease low back pain
- Supporting the lordosis of the lumber spine has been shown to increase the stability of the spine as well as to decrease low back pain.

Plast. Reconstr. Surg. 127: 225, 2011

Toranto R. *Plast Reconstr Surg*. 1990; 85:545–555.

Toranto R. *Plast Reconstr Surg*. 1988;81: 777–779

McGill SM, *Clin Biomech*.2000;15:777–780.

Functional abdominal wall reconstruction improves core physiology and quality-of-life

Cory N. Criss, MD,[a] Clayton C. Petro, MD,[a] David M. Krpata, MD,[a] Christina M. Seafler, RN,[a] Nicola Lai, PhD,[b,c] Justin Fiutem, MS,[c] Yuri W. Novitsky, MD,[a] *and* Michael J. Rosen, MD,[a]
Cleveland, OH

(Surgery 2014;156:176-82.)

finalità

- determinare l'effetto della ricostruzione della linea alba sulla funzione della parete attraverso il dinamometro
- misurazione della Qol pre e post AWR

metodo

- 13 pz sottoposti a TAR
- analisi della flessione con biodex 3 pro *(protocollo isocinetico e isometrico)*
- Questionario HerQles pre e post op

caratteristiche	valore
maschi/femmine	7/6
età (aa)	54 (36 – 69)
BMI (kg/m²)	31 (20 – 46)
chirurgia addominale pregressa	4 (1 – 6)
precedenti riparazioni	2 (0 – 6)
storia di open abdomen	1/13
larghezza difetto (cm)	12,5 (5 – 19)